

# “RECOGNITION OF COMMON BROILER DISEASES”

UNIVERSITY OF  
MARYLAND  
EXTENSION



## GROWER LUNCH BREAK NOTES DECEMBER 2, 2020


Jon Moyle introduced **Dan Bautista, DVM**, previously the Director of the University of Delaware’s Lasher Lab. Dr. Bautista, now working with **Zoetis** (a sister company of Pfizer), continues his career of supporting industry, growers, and students through diagnostics.

*So much information covered in this talk – please take advantage of the following:*

**Link to watch the recorded Zoom:**

<https://umd.zoom.us/rec/share/U5dQMOKJIUfNIUGfFXLCrQ7NsEPc8bdumzm9SHYkixgLiQAOebkfidPa8RauRJ1K.YLWerUvyMCpc09UT> Passcode: 41sa.aUG

The following Notes gives you a taste of the first half of Dr. Bautista’s presentation.



### Common Broiler Diseases and Case Scenarios

2020 DPI National Mtg on  
Poultry Health And Processing,  
Ocean City, MD

---

#### **Daniel Bautista DVM, MS**

Senior Technical Services  
Veterinarian

**Zoetis/ US poultry**

daniel.bautista@zoetis.com



Dr. Bautista did a quick visual tour of common broiler disease/lesions.

**ILT/LT/'Trach" (Laryngotracheitis) – Signs and Lesions**

- \* Blood-tinged, weeping eye, sudsy
- \* Almond or football shaped eye
- \* Wiping eye on the wing
- \* Bloody mucus
- \* Gasping/squealing - wind pipe 'tracheitis'
- \* Solid, cheesy tracheal exudates
- \* Herpes viral infection

If they are showing signs, means 1-2 weeks infected already. Incubation period, time of infection to time they are showing signs. If you are seeing signs or deaths, they have been shedding the virus for a while.

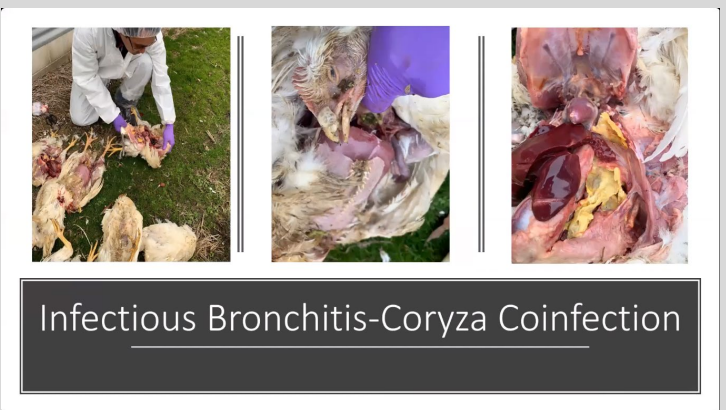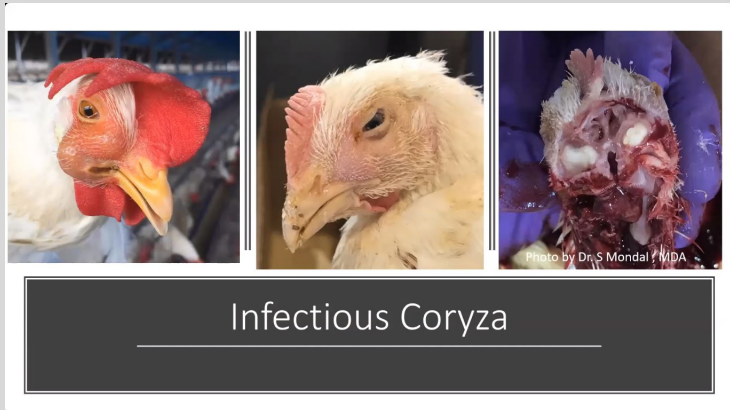There are two LT vaccines, a water with the live virus given at 2 weeks of age – birds drink within an hour. Most of the other companies are on the egg vaccination – or in ova or in the egg vaccination. **Biosecurity** is still vitally important.

**Infectious Bronchitis: Respiratory Form - Air sac condemnations**

- \* 90% of what we deal with other than LT
- \* Pneumonia – lungs *should be* collapsible but with pneumonia, lungs are solid and don't contain air
- \* Thoracic airsacculitis – cheesy lesion, solid puss

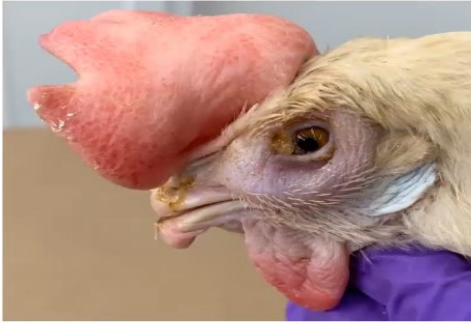**Renal Form (NIBV) – Flushing Diarrhea**

- \* Watery diarrhea
- \* Kidneys full of uric acid



Coryza was introduced to Delmarva over a year ago. The sinuses are blocked with cheesy lesions and the birds have puffy sinuses.

## Infectious Coryza Mixed Infections



Layer: Coryza, MG, MS+ by RT-PCR



Backyard Flock: Coryza, MG, MS, ILT + by RT-PCR

Dr. Bautista suggests staying away from backyard flocks if you are a commercial grower – you may be exposed to a lot of infectious diseases.

Next Dr. Bautista talks about ‘navels’ and how they are the gateway to bacteria. If the navel is open, it will be prone to infection from hatch to early growth if they

are stressed. Mostly *E. coli*. Get used to looking for unhealed, inflamed or infected navels.

Sanitation from the hatchery all the way to the grower – watch for molds

**Early Clostridia Infection** - unhealed navels; dirty eggs; green spots in the liver, retained yolks; cheesy peritonitis

**Bacterial Chondronecrosis and Osteomyelitis** - you are the vanguard as growers, after 7 days, cull birds that are dragging their feet, cheesy legions inside caused by bacterial infection. You don't want growing 5 weeks, dying, and affecting your feed conversion.

### Chick Quality Issues: Critical Points

#### Breeder Farm:

- Initial egg weight
- Egg sanitation
- Enteric health

#### Hatchery:

- Egg storage time – egg age
- Exploding eggs during ‘In Ovo’ vaccination
- Tray washing and disinfection
- Malfuction of separators and conveyers
- Poor chick selection

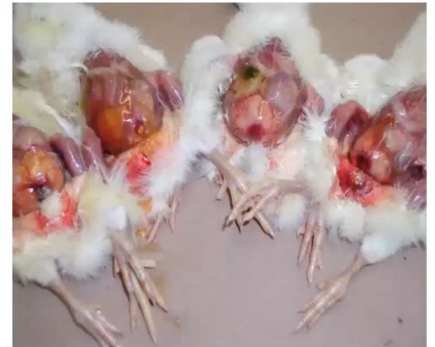#### Broiler Farm:

- Rough handling during transportation and placement – stress to chicks
- Brooding conditions - temperature, litters and air quality, water flow, etc.

### Leg Problems

- Fast growing birds need required nutrition
- Rickets – not enough calcium – they may not be eating enough
- TD – Tibial Dyschondroplasia
- Femoral Head Necrosis
- Cellulitis/IP
- REOviral Arthritis and Tenosynovitis – fat, broad legs, lame – dark warm environments, immune suppressed
- Gumboro Disease
- Ruptured tendon (Reovirus/rough handling/big heavy birds), sometimes they grow too fast, tendon snaps
- Kinky Back – legs stretched, out sitting on tails – spinal abscess, bacterial disease in the spine, paralysis

### Unhealed navels & infected yolk sacs - Omphalitis



Mostly *E. coli* isolated

**Coccidiosis**

Costs \$3 billion/year worldwide – very common, even on Delmarva, well controlled by medications that have to be rotated so we don't overuse them. Must have a rest period (rotation).  
Red balloon guts, jelly-like droppings  
Coccidia is the parasite infection. Microscopically they look like little deviled eggs. Intestinal villi.

**Nonspecific Enteritis (no cocci/NE)**

Runny gut – feed related  
Feed interruptions or litter eating due to prolonged dark periods  
Biogenic amines (ie. Rancid oils, MBM)  
Nutrient inhibitors in some soybean meal batches  
Some components of 'all-veg' diets

**"Derm" Gangrenous Dermatitis**

Look for red and weepy skin, sudsy jelly-like, froth (examples in his presentation)  
If your floors are always wet, you'll have a challenge  
Maintain litter quality

**Heat Stroke**

Red, but not Derm. If you have a house that is too stuffy, they don't sweat, so they don't handle heat  
Eliminate dead spots in houses. Birds emit a lot of heat, there is opportunity for them to be overheated

**Inclusion Body Hepatitis**

IBH liver lesion and IBH jaundice (yellowish liver)  
Can be set into floors – have a good program to

**Marek's Leukosis (tumors)**

Tumors, vaccine failure.

**Spotty Liver Disease** (Campylobacter hepaticus) in commercial chickens with outdoor access. Something new.

Thank you Dr. Bautista for your excellent presentation!

---

**SET YOUR CALENDAR:** No December 16 Grower Lunch Break. We will announce the collaboration with Delaware Ag Week in late January. Pick up with Wednesday discussions February 3, 2021!

